

Body condition score in antelopes

Assessing the condition of your animals gives you an indication of the overall health of your animal is thus an important management tool. Both very thin or fat animal are prone to different health risks and will have suboptimal reproduction rates. In this article we will focus on antelopes.



Changes in body condition

It is important to recognise animals losing weight as early as possible since this allows time to identify the underlying cause(s) and take corrective measures to prevent animal losses.

There are many **causes for an animal being in poor condition**. The most obvious is insufficient nutrient intake, which may be primary starvation (e.g. in a drought), or due to poor food quality (unpalatable or poorly digestible food). An often overlooked cause is where nutritional demands exceed food intake (e.g. pregnant or lactating animals). Other important causes for an animal losing condition would be an inability to eat (e.g. bad teeth or other lesions in the mouth/jaw but also competition around feeding areas where timid animals are chased off by dominant animals in the herd). Disease can reduce body condition due to a loss of appetite and/or due to a loss of nutrients (e.g. worms, diarrhoea etc.).

Thus, when assessing an antelope's condition, keep in mind that their reproductive status influences both behaviour patterns as well as nutritional needs. For instance, a female in late pregnancy or one with a lamb or calf at foot, has much higher nutritional demands. If these are not met by food availability, these animals will lose body condition. Males on the other hand are more likely to lose condition during the breeding season when they are busy fending off competitors.

1

Body Condition Score System

A number of 'Body Condition Score' (BCS) systems are used in different domestic animals. All work on a numbering system (from 1 – 5 or even to 9), where the lowest number is usually allocated to the animals in very poor condition, and the highest number to obese animals. After assessing several criteria and body regions, an animal is allocated a specific score.

When working with wildlife one often has to observe animals from a distance, and frequently does not get the chance to watch an animal for a long time before it disappears in the bush. To streamline things, we like to work with a simple 4-scale system, whereby 1 suggests a very poor condition, 2 poor condition, 3 is ideal, 4 is fat.

It takes time and practise to become proficient in applying a BCS system accurately. Spend time with the animals, observe them, get to know them and be aware of normal anatomic features in specific species.

Because one often sees the animal for only a short time and at a distance, we recommend that you always have a binocular or ideally a camera (with proper zoom) at hand when going into the field. Once back at home, you can take your time to view the pictures on your computer to properly evaluate the BCS.

Dr. Ulf Tubbesing

✉ P.O. Box 50533 Bachbrecht, Windhoek
☎ +264 (0) 81 128 0350 [Wildlife Vets Namibia](#)
🌐 www.wildlifevetsnamibia.com

For valuable animals it is a good idea to take comparative photos on a regular basis. This provides an ideal and permanent record of the animal's trends in overall condition. Such a photo record will also enable you to spot (and monitor) early and minor changes in body condition. Remember, early diagnosis and intervention is always the best remedy.

To keep track of the different BCS of your antelope, ideally use a table like the one below, where a BCS score (and photo) is taken on a regular basis. This is only feasible if you can identify your animals, by either ear tags or other visual characteristics. If you see changes in the BCS, note down the likely cause of this. If there is no likely cause, the antelope might be sick.

Sable	Jan	Feb	Mar	Apr	May	Jun	Jul	Aug	Sep	Oct	Nov	Dec	Remarks
A20	2	2	2	2	3	3	3	3	3	3	2	2	Calved in Jan, good rains + grass cover in April. Poor grass cover in Nov
A23	3	3	2	2	2	3	3	3	3	3	3	3	Residual pasture but drought conditions result in condition loss in March. Supplemental feeding from mid-April, good condition recovery by June
A24	3	3	2	2	1	1	2	2	3	3	3	3	Young bull in same group as 2 above NOT picking up condition due to feeding competition – being pushed out. Fed at separate spot 100 m away from mid-June onwards
B45	3	3	2	1	2	3	3	3	3	2	2	3	Heifer rapidly losing condition. Darted and checked 10 Apr. Treated for heavy worm infestation

Body regions for assessing condition

Similar to determining the body condition score in domestic animals, we also assess different body regions in antelope. First off, we look at the general appearance of the individual, paying specific attention to its behaviour. Sick animals tend to be separated from the herd, are not seen eating, and because they stop grooming behaviour tend to have a heavier parasite burden (flies and ticks). Animals that are thin due to insufficient food intake, tend to roam with the herd and are keen to eat (Figure 1).


Now we look at those body regions that give the best indication of body condition, namely the neck, shoulder, ribs, spine and hip area. Evaluate the muscle coverage (fullness) of these areas. This is used to identify whether an animal is of a healthy weight, too thin, or too fat. Antelope species, in contrast to domestic animals, rarely have a thick layer of fat.



Figure 1 Eland cow shows poor body condition, has mouth lesions and a heavy tick and fly infestation, suggesting disease rather than starvation as the problem © MGM farm.

Figure 2 shows the important body regions to evaluate when assessing the body condition score.

Dr. Ulf Tubbesing

✉ P.O. Box 50533 Bachbrecht, Windhoek
☎ +264 (0) 81 128 0350  [Wildlife Vets Namibia](#)
🌐 www.wildlifevetsnamibia.com

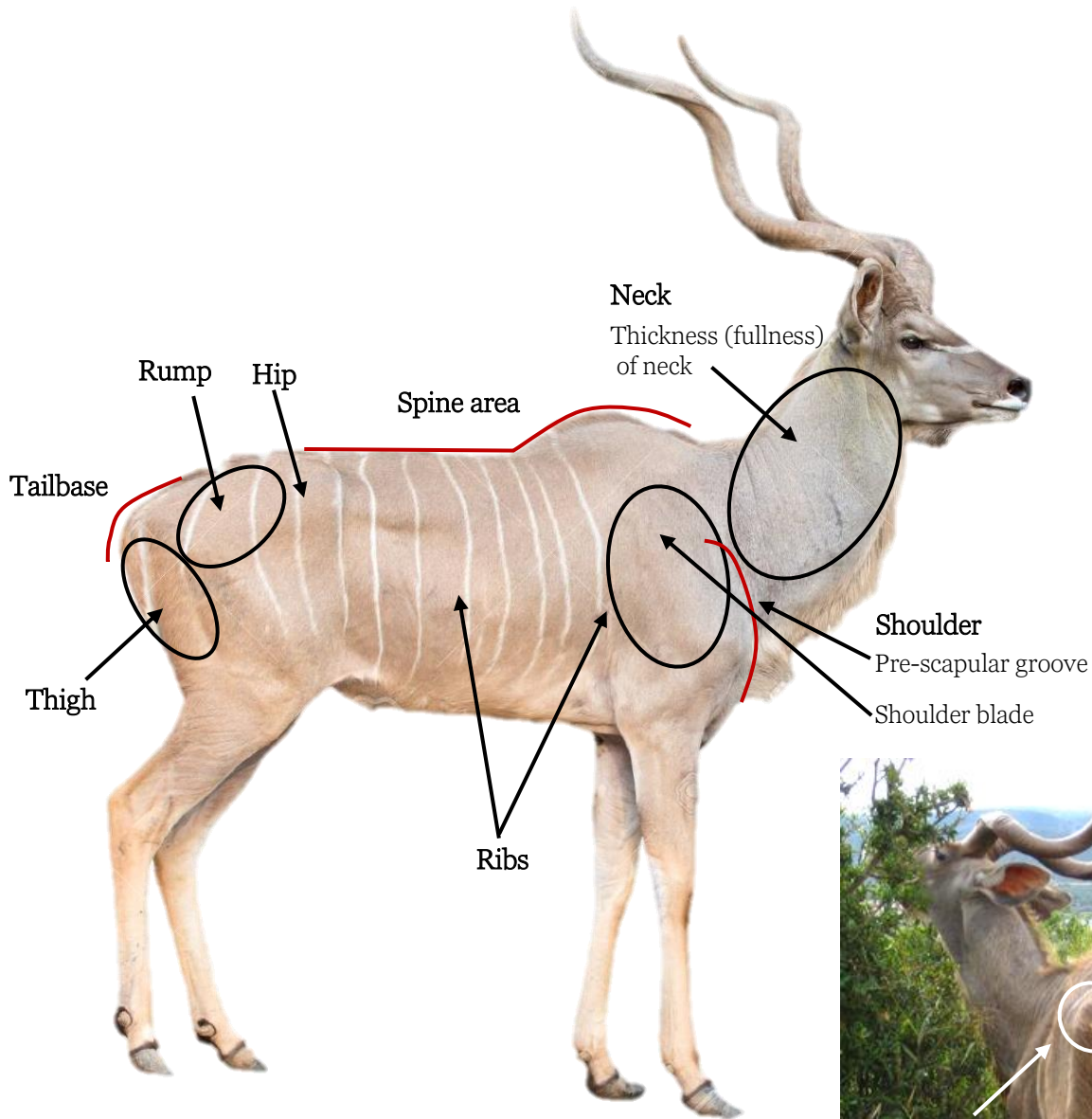


Figure 2 Key areas for assessing body condition score in antelopes



Kudu seen from the back, indicating the pins (sitbeen) © [Brian Burger](#)

Neck

The neck should appear full and well-muscled. Be aware that many male antelopes, esp. during the breeding season, have a thicker neck than females (e.g. kudu, nyala). With a worsening body condition, the muscles in the neck waste away, making the neck narrower. The muscles in front of the shoulder blade hollow out, and the pre-scapular groove becomes more visible.

Shoulder

The shoulder blade should be well-covered by muscles. With loss of condition, the shoulder area becomes flattened and the spine of the shoulder blade eventually the becomes well-visible.

Ribs

The ribs at the centre of the rib cage should be slightly visible. As the condition drops, ribs become notably visible, eventually as deep depressions in between the ribs.

Spine

The spinal area must be rounded, with muscles 'filling' the gap between the ribs and spine. When the condition worsens, the muscle layer gets thinner and the spine becomes more visible. Eventually the back will hollow out, and the spine seems to stick out more and more (Figure 3).



Figure 3 Spine as seen from the back of an animal. The red colouration indicates muscles/fat. The first picture shows a skinny animal; the spine is very noticeable, there is no fat and ribs will be visible. The second picture is ideal; the spine does not stick out too much, it is not hollow between the ribs and spine. The third picture shows an obese animal; the spine is very rounded by the fat.

Rump and thigh

Both the rump and thigh should be rounded without obvious body points protruding (sticking out). With loss of condition the bony points become more visible, the areas where muscles are supposed to be become hollow.

Hip bones

Normally the hip bones are visible as being round and smooth. With deteriorating condition, the flanks are falling in and the rump muscles waste away with the hip bone protruding prominently.

Pins

The pins (sitbeens) are visible, but rounded. With loss of condition, the pin bones become more prominent and sharp.

Tail base








The tail base should be 'on level' with the surrounding fat tissue. With a worsening condition, the tail base starts sticking out and the adjacent fat and muscles become hollow (Figure 4).



Figure 4 Arabian oryx as seen from the back, showing an ideal condition (left) and thin condition (right). Note the differences of the tail base and pins. © El Alqamy

Dr. Ulf Tubbesing

✉ P.O. Box 50533 Bachbrecht, Windhoek
 ☎ +264 (0) 81 128 0350 📱 [Wildlife Vets Namibia](https://www.facebook.com/WildlifeVetsNamibia)
 🌐 www.wildlifevetsnamibia.com

			
			5
<p>Condition 1: Emaciated There is little muscle in the rump and thigh and no fat cover. Hip and pin bones extremely prominent and sharp. Tail base very bony. Shoulder blade and ribs well visible. Spine is prominent, groove between spine and ribs well visible.</p>	<p>Condition 2: Thin Rump and thigh are hollow. Hip and pin bones prominent. Tail base slightly bony. Shoulder flat, slightly bony. Ribs well visible. Spine prominent, groove between spine and ribs obvious.</p>	<p>Condition 3: Ideal Rump and thigh filled, slightly rounded. Hip bones slightly visible, pin bones and tail base rounded. Shoulder well-muscled. Ribs slightly visible. Spine slightly visible, groove between ribs and spine well-filled.</p>	<p>Condition 4: Fat Rump, thigh and tail base are rounded and bulging. Pin bones concealed. Ribs are covered, spine is rounded.</p>

Above photos: Body condition score for deer © [Deer Industry New Zealand](#). Below photos: Emaciated kudu in Colombo Zoo Sri Lanka © [Scox1313](#), Thin kudu in Tarangire NP, Tanzania © [Moshi Maasai Experience](#), Kudu in ideal condition in Kruger National Park © [L0k1m0nk33](#)



Figure 5 Eyes of a healthy sable on the left © [J. Hayes](#) and a very emaciated roan bull on the right © [M. Bijsterbosch](#)

When you look at Figure 5, you can see the difference of the eyes between a healthy and very thin antelope. On the right photo, note the severely sunken-in eyes. The most common cause for sunken-in eyes is severe emaciation or dehydration in which case both eyes are equally sunken in. In rare cases, damage to some nerve fibres may also cause a sunken eye but this is often limited to one side only.

How to improve body condition in antelopes?

First of all, one must try and find out why the antelope is in poor condition. Is it because of no or little food availability (e.g. drought, certain minerals missing)? Or is there maybe a medical cause (e.g. worn teeth, worms)? Is the animal pregnant, or nursing a lamb or calf? Can the season be of influence (e.g. very cold)? Is it an individual animal, or the entire herd?

Because wildlife is highly diverse, specialized, and difficult to manipulate, feeding game is not as easy as feeding livestock. Extensively farmed game is usually not used to supplemental feeding and often take weeks before getting accustomed to it. For more information on what influences feeding behaviour in animals, read and download our online article 'Change, the driver of feeding behaviour in (wild) animals' [here](#).

Dr. Ulf Tubbesing

✉ P.O. Box 50533 Bachbrecht, Windhoek
☎ +264 (0) 81 128 0350 [Wildlife Vets Namibia](#)
🌐 www.wildlifelivetsnamibia.com

Little grazing

If you notice your animal(s) start losing condition and you have little grazing, it is best to start feeding your animals at an early stage, before the body condition drops severely. In this way you will minimise stock losses and reduce the grazing pressure on your pasture to ensure a quicker recovery after the first rains.

It is important to feed in multiple different areas of the farm **and, at each feeding site**, spread the feed out over a bigger area. This has multiple reasons:

- 🐾 It minimises dominant animals chasing timid ones away thus ensuring that all the animals get a chance to eat (older cows and young calves).
- 🐾 Habitat degradation is minimised by avoiding excessive animal density limited to one spot.
- 🐾 Reseeding can take place on the feeding sites. While eating, the animals will break soil crusts, trample hay/grass seeds into the ground, and defecate/urinate in those areas, thereby creating a “well prepared and fertilised” seed bed for the next rainy season. It should be obvious that the habitat will benefit greatly from you continuously shifting these feeding sites to avoid excessive trampling and to ensure that as big an area as is practically feasible is benefitting from this rehabilitation process.

Read more about what you could give your animals as supplemental feeding in our online article [‘Feeding wildlife during a drought’](#).

Medical reasons

There can be many different medical reasons why an animal is losing condition. The best thing is to consult your veterinarian. Take photos of the animal, describe its behaviour and describe how the animal has changed over time. If an animal dies, make the most out of your loss by performing a thorough and systematic PM (Post-Mortem) examination. Take many good quality photos and send them, together with appropriate background information to us via WhatsApp or email. We have developed a special 2-day course for farmers and farm managers where we teach you how to do a proper PM and take photos that will quite likely enable us to provide you with a diagnosis and management advise. For more information, have a look at our online [PM course outline](#).

One reason for a worsening condition might be internal parasites (e.g. tape worms, round worms, flukes). Especially in small camps animals are more likely to be infected with internal parasites. The best thing would be to check the faeces, do you see worms? Your veterinarian can check the faeces for worm eggs. The type of parasite should be identified, and then the type of drugs can be determined. Be aware for resistance, the intensive use of anti-parasitic drugs in especially the livestock-industry has led to a widespread resistance against anti-parasite drugs. Treatment should always be in consultation with your veterinarian.

Dr. Ulf Tubbesing

✉ P.O. Box 50533 Bachbrecht, Windhoek
☎ +264 (0) 81 128 0350 📱 [Wildlife Vets Namibia](#)
🌐 www.wildlifevetsnamibia.com