

# NEWSLETTER JUNE

## In this newsletter:

- 🐾 [Tortoise shell](#)
- 🐾 [Post-Mortem roan heifer](#)
- 🐾 [Brown hyena immobilization](#)

Dear clients,

We hope you managed to stay warm during the cold spell! Quite a sight to see some parts in Namibia with snow! Now its time for some hot chocolate, a blanket, and our newsletter! In this edition we talk about the fascinating tortoise shell and we discuss a Post-Mortem case of a roan. Lastly, we talk about our recent trip to the Sperrgebiet where we immobilized brown hyenas.

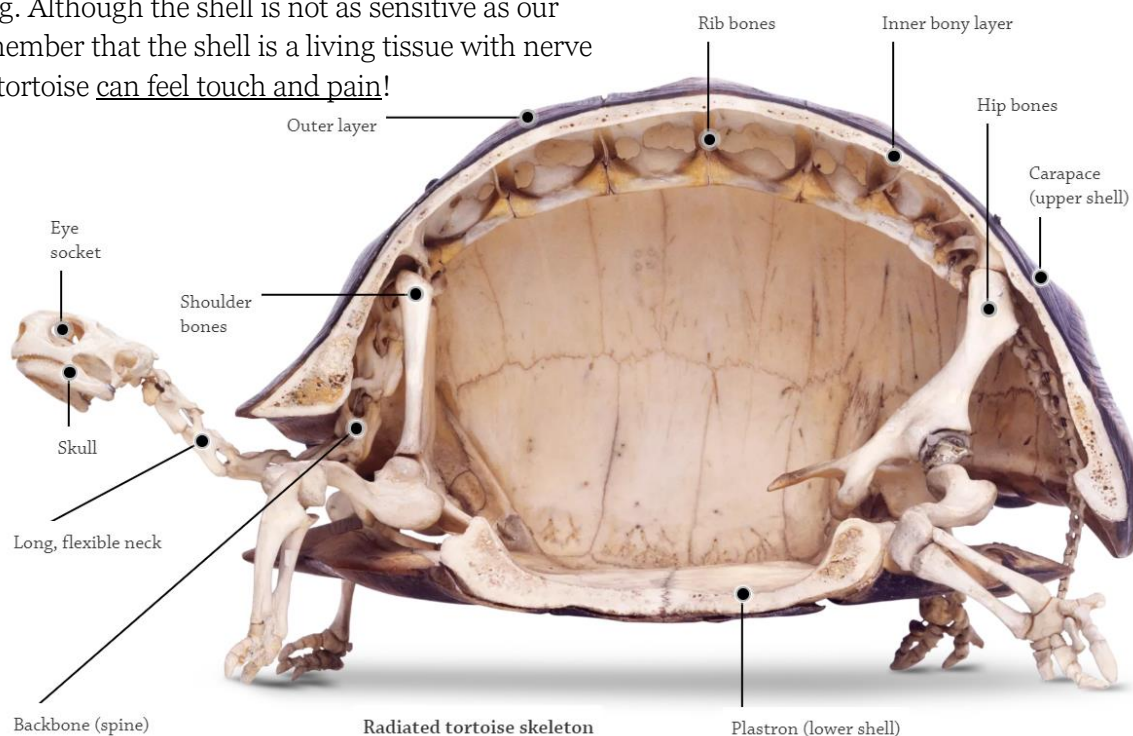
Kind regards, the Wildlife Vets Namibia team

## TORTOISE SHELL

Tortoises are fascinating animals, they have been roaming Earth for million of years, and have developed an outer 'armoured suit', which is their primary defence mechanism against predators. First of all, its difficult for a predator to bite/scratch through the shell, secondly, due to the rounded shape it is also difficult for a predator to get a good grip. The shell also provides stability to the tortoise's body and provides shelter from harsh weather. When there is danger, the tortoise's flexible neck can retract the head inside the shell.

The shell is part of an exoskeleton, which means that part of the skeletal system is on the outside of the animal. The shell is made up of two main components. The plate underneath is called the *plastron*. In most male tortoise species, the plastron is hollowed or rounded inward, which allows them to mount females. The outer top part of the tortoise shell is called the *carapace*. The shell is made out of several small bones that are covered by keratin plates, called *scutes*. As the tortoise grows, extra layers of keratin are added underneath the existing layer. The shell is fused to the inner ribs and spine (so no, tortoises cannot slip out of their shell 😊).

Many people think that the shell of tortoises is just a hard bony structure without any ways of feeling. Although the shell is not as sensitive as our skin, it is important to remember that the shell is a living tissue with nerve cells. This means that the tortoise can feel touch and pain!



The skeleton and shell of a radiated tortoise – [DK Findout!](#)

## POST-MORTEM ROAN HEIFER

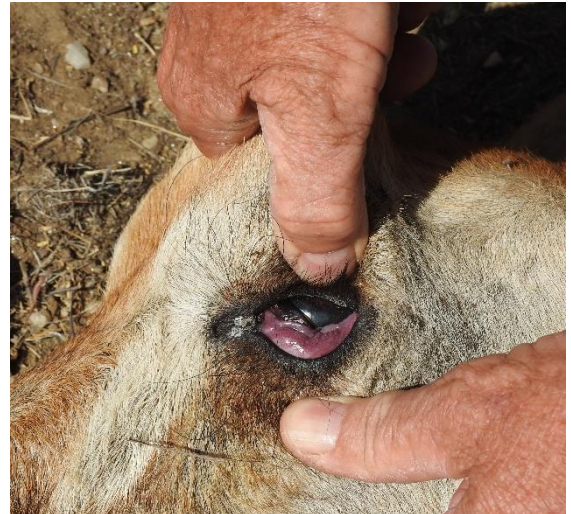We have been advertising and talking about our Post-Mortem course a lot lately. Perhaps you are getting a bit tired of it 😊 However doing a PM (nadoodse ondersoek) is really important! You as a farmer and us as vets can gain a lot of knowledge – you to keep your herd in an optimal condition, and we learn more about general diseases in Namibia. In this article we would like to show you how much information you could gain. We will first give you the history, and the PM findings. As you read through the text and photos, think for yourself what this can mean. At the end we will explain what our interpretations were.

### History

This case happened during the harsh drought of 2019. The roans were fed lucerne and boskos. Two roan heifers had died recently. A third heifer appeared sick, and we were called out. By the time we got to the farm the roan heifer unfortunately died.

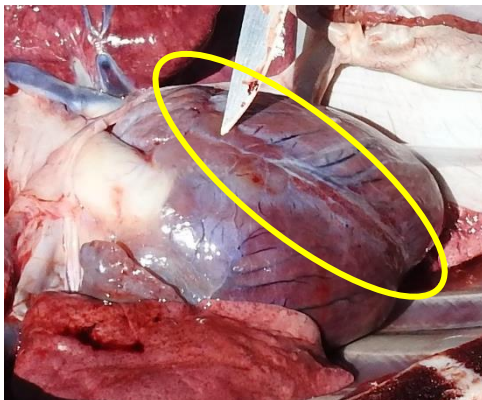
### External examination

The heifer appeared to be bloated, even though she died just a few hours ago. She was in a poor body condition, and her mucous membranes were blue/purple.

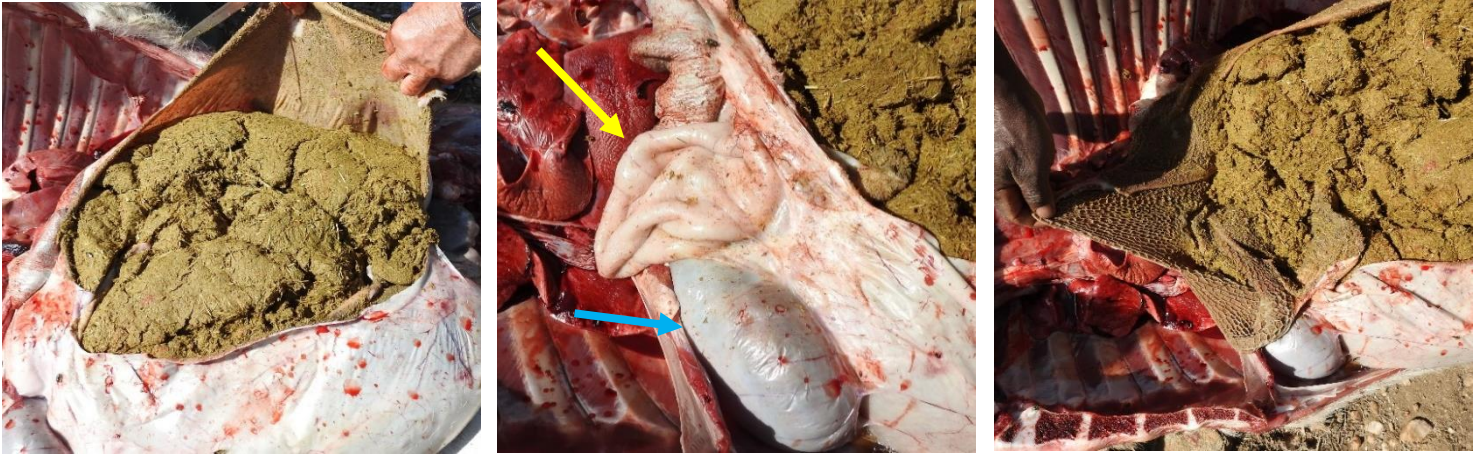


### Post-Mortem findings

On the rumen (grootpens) we found haemorrhages (small bleedings). Around the coronary groove of the heart was no fat.



The other organs did not show major abnormalities. The rumen was very full, and the content was dry and impacted. The next stomach, the reticulum (ruitjiespens) was completely empty (yellow arrow). The following stomachs, the omasum (blaarpens – blue arrow) and abomasum (melkpens) were impacted with dry content. The duodenum (first part of the small intestines) was completely empty.



The omentum (thin membrane that covers the stomachs and intestines) did not have any fat (see-through) and no fat was observed around the kidneys.

### So now what?

What was remarkable for you in this case? You might have thought all the lack of fat is not right... Very correct! The poor body condition, and especially the absence of fat around the heart, omentum and kidneys indicate that the roan was starving. Fat around the organs is the last fat that gets absorbed by the body – meaning a very poor body condition.

The blue mucous membranes are abnormal, indicating a lack of oxygen (cyanosis). This was likely caused by suffocation due to rumen pressure on the diaphragm.



The third observation is the bloat. As the roan was opened up, small bleedings were found. Remember this... dead animals don't bleed. So, the bleedings on the rumen happened before the animal died. This is an important observation; would there not have been bleedings, then the bloat most likely happened after the roan died. In this case, as the roan bloated, the small blood vessels teared and started to bleed.

### Conclusion

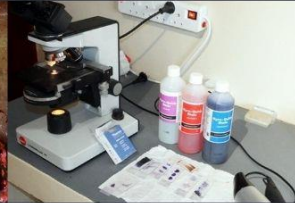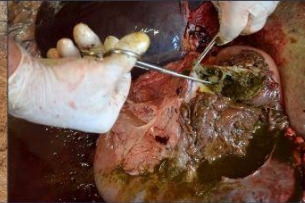The conclusion is up to your vet. With your info and photos, the vet should be able to 'make an educated guess'. The fresher the carcass, the better the vet can help. The absence of fat around the heart, omentum and kidney indicated that the roan was starving. Her rumen was completely full and impacted, but the food did not pass through. This suggests poor digestibility of the food. Most likely, the lignin content of the boskos food was too high (late stage of the season with no green left around the branches), making the boskos of inferior quality. This resulted in starvation and disturbance of rumen flora, and leading to bloat.

### Advice

Drastically reduce or take away the boskos, and feed good quality lucerne and game pellets.

Wildlife Vets Namibia & SAROA Safari Lodge present...

# POST-MORTEM COURSE

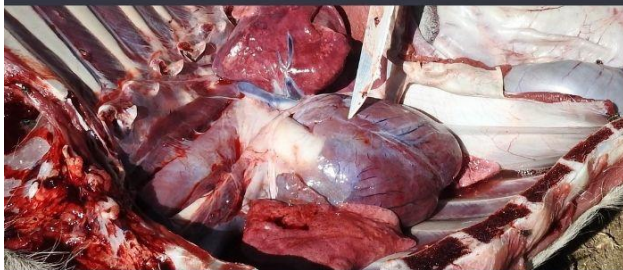


## WHY THIS COURSE?

Since Namibia is such a vast country, getting a vet in when an animal has died is not always practical.

However, doing a Post-Mortem (PM - naadoodse ondersoek) on a fresh carcass greatly improves the chances of finding out why an animal has died.

In 1.5 days, we teach you the basic principles of doing a PM, how to take proper photos and how to take samples. This information you can send to your vet, and together you have a good chance of figuring out what happened to your animal. This knowledge will help you to improve the general herd management, and possibly prevent a disease from spreading.



## FOR WHO?

This course is designed for farmers, managers and other interested persons. Although we focus on wildlife, the course is very well suitable for livestock owners, since the anatomy, many diseases and PM findings are the same.

During the course we give several lectures so you understand why and how a PM should be done. On the final day we do an actual PM examination, in where we guide you through the procedure from A to Z.

## COSTS?

Course fee:  
N\$ 1700 p.p.

Accommodation fee:  
N\$ 850 p.p./night

Day fee: N\$ 500 p.p.

Prices are excl. VAT. The course fee is inclusive of lecture material (you will get the PPT's and extra useful material in a PDF form on a USB stick), the lectures itself, use of the facilities, and a practical PM demonstration. The accommodation fee includes all meals. It is possible to sleep over the night before the course starts and/or stay longer to enjoy a little holiday!

## WHEN?

09 - 10 July 2022  
SAROA Safari  
Lodge  
(Nina district)



To receive the course outline with more information, contact us at:

✉ [mariska@wildlifevetsnamibia.com](mailto:mariska@wildlifevetsnamibia.com)

☎ 081 382 8473 📞 +316 4369 3095





*The brown hyenas rely on the seal colonies for their food © M. Bijsterbosch*

## **BROWN HYENA IMMOBILIZATION**

Last week we did a special trip... We drove all the way south of Lüderitz, into the Sperrgebiet, to immobilize some brown hyenas! The brown hyenas that inhabit the Namib Desert Coast are special in the sense that they are the only large predators around (their only competitors are the black-backed jackals) and they forage mainly on Cape fur seal pups. It is unknown where most of the hyenas live (den), but they regularly visit the seal colonies for a meal. Some of the hyenas just scavenge, but other individuals are active hunters. We immobilized three hyenas, with the aim of fitting a telemetry collar on them.

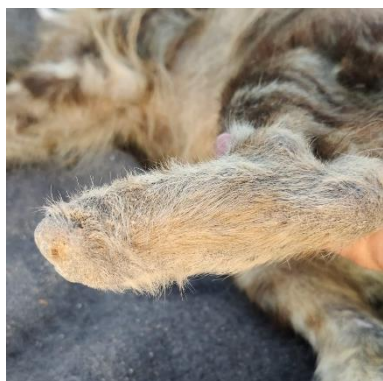The telemetry collars provide valuable data, which will provide the researchers with more information about the elusive brown hyena. Recently a tourism development plan was developed for the Tsau//Khaeb National Park (Sperrgebiet), which includes small-scale tourism initiatives to visit the seal colonies. As these colonies are the only food source for the brown hyenas and black-backed jackals, it is important that tourism activities do not disturb the animals in any way. The brown hyenas most likely live in the hills up to a few km inland, and feed at the coast. However, nobody knows where the hyenas exactly come from and via which routes they travel. The tourism access road would be located in the area that the hyenas might use to cross to the coastal area. With the telemetry data, the researchers can hopefully figure out what routes the hyenas use. This information can then be used to design an optimal management plan which optimises the tourist experience and, minimises any disturbance to the hyenas.

In the first hyena we immobilized, the telemetry collar we fitted a year ago needed to be removed because it was damaged and non-functional. Fights between hyenas are not uncommon, and unfortunately the collar was bitten right on the spots where the wiring was... The new collars are reinforced and stronger. Fortunately, we saw this hyena again, and we could remove the non-functional collar. From initial data collected from the collar (before it was damaged) the researcher now knows that this hyena remains in the area. He was thus only re-collared with a visual collar on (very light-weight), which makes him more easily recognizable on camera traps. From each immobilised hyena samples (hair, tissue, blood etc) and measurements are taken.



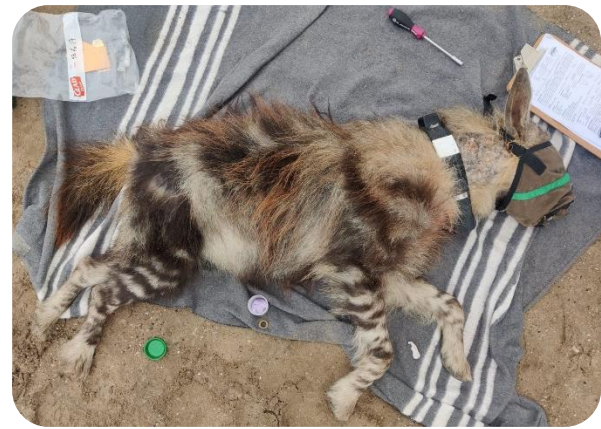*Brown hyena that received a visual collar © M. Lemerle – Brown Hyena Research project*

The second hyena we immobilized was an old female. This lady had a rough life; the one foot was bitten off during a previous fight (stump healed out well), and her other leg was dislocated at the hock joint. The healing powers of animals are amazing! She is still going strong, even though now mostly scavenging off other hyena kills! Only samples were taken and she was reversed again.




The third hyena was a young, elusive male that is rarely spotted, so an interesting candidate for a telemetry collar! This male was in great condition, and weighed 43 kg!

We would like to thank Marie Lemerle from the Brown Hyena Research Project for taking us into her domain and sharing her extensive knowledge with us! It is a very special experience to sit and watch the hyenas, the jackals, the seals and all the birds coming and going in this vast landscape. We would also like to thank conservationists and filmmakers Ivan Carter, Sean Viljoen and Keenan Ferguson for sponsoring and documenting the whole trip. The episode will be shown towards the end of the year on [Earthx TV](#). This is an online channel that broadcasts interesting conservation videos for free. Worth to have a look!



*Brown hyena that received a telemetry collar*  
© M. Lemerle – Brown Hyena Research

As you can imagine, immobilizing these rather skittish hyenas is a costly exercise. The telemetry collars, getting a vet all the way there for several days, the darts... There is another telemetry collar that we would have loved to deploy, but unfortunately we ran out of time, and the weather conditions (esp. the winds over 40-50 km/h) got very harsh, making it impossible to dart. We hope very much that enough funding can be obtained for more collars. If you would like to help, please visit [the website of the Brown Hyena Research Project](#).



Feb. 22, 1952: Veterinarians attempt the first skunk de-scenting operation.

DR ULF TUBBESING  
P.O. BOX 50533, BACHBRECHT,  
WINDHOEK  
+264 (0) 81 128 3050  
[ULFT@AFRICAONLINE.COM.NA](mailto:ULFT@AFRICAONLINE.COM.NA)

MARISKA BIJSTERBOSCH  
+264 (0) 81 382 8473  
+31 (0)6 4369 3095 (WHATSAPP)  
[MARISKA@WILDLIFEVETSNAMIBIA.COM](mailto:MARISKA@WILDLIFEVETSNAMIBIA.COM)

[WWW.WILDLIFEVETSNAMIBIA.COM](http://WWW.WILDLIFEVETSNAMIBIA.COM)  
FACEBOOK: [WILDLIFE VETS NAMIBIA](#)  
YOUTUBE: [WILDLIFE VETS NAMIBIA](#)

